

Oral Manifestations of Metastatic Diseases & Lymphoid Neoplasms

Zeming (Eileen) Zheng, Elizabeth Philipone

Department of Oral Pathology, Columbia University College of Dental Medicine, New York, NY



INTRODUCTION

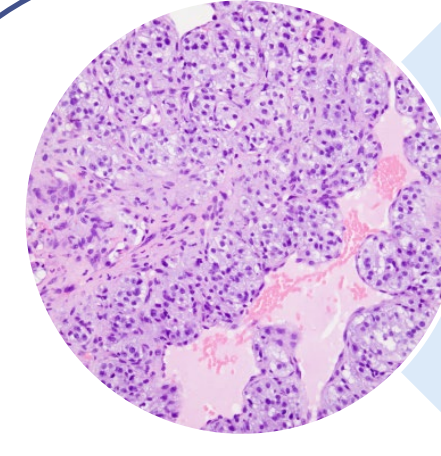
- Metastatic cancer and lymphoid neoplasms can manifest in the oral cavity
- Metastatic Diseases**
 - 1-3% of malignant oral neoplasms
 - Jaw bones, oral soft tissues, or both
 - ~25% of patients presenting with oral metastatic disease unaware of having primary cancer
- Lymphoid Neoplasms** (lymphomas, acute/chronic lymphocytic leukemias, and plasma cell neoplasms)
 - Low grade → localized disease limited to oral cavity
 - High grade → oral tumor is manifestation of widely disseminated disease
- Both can mimic inflammatory conditions (i.e. periodontal disease or osteomyelitis)

OBJECTIVE

To document the oral manifestations of metastatic and lymphoid neoplasms seen among the Columbia University Irving Medical Center (CUIMC) Department of Oral Pathology's patient population, including:

- Patient demographics
- Biopsy diagnosis + location
- Clinical presentation + diagnosis
- History of systemic disease
- Origin of the primary – metastatic diseases
- Disease classification, localized/disseminated – lymphoid neoplasms

METHODS



SEARCH CUIMC Department of Oral Pathology's biopsy database for cases of metastatic or lymphoid neoplasms

RECORD sex, age at diagnosis, biopsy location, clinical presentation and diagnosis, histologic/biopsy diagnosis, history of systemic disease



CROSS-REFERENCE each patient's biopsy report with electronic medical record in Epic to confirm presence/absence of prior known history of systemic disease

Photo courtesy of Creative Commons



DATA ANALYSIS IN EXCEL

- Total cases
 - Metastatic disease vs. lymphoid neoplasm cases
 - Initial manifestation vs. known history of systemic disease cases
 - Bone vs. soft tissue presentation cases
 - % cases with correct clinical diagnosis
 - % cases with suspected benign/infectious clinical diagnosis
- Photo courtesy of Creative Commons*

RESULTS

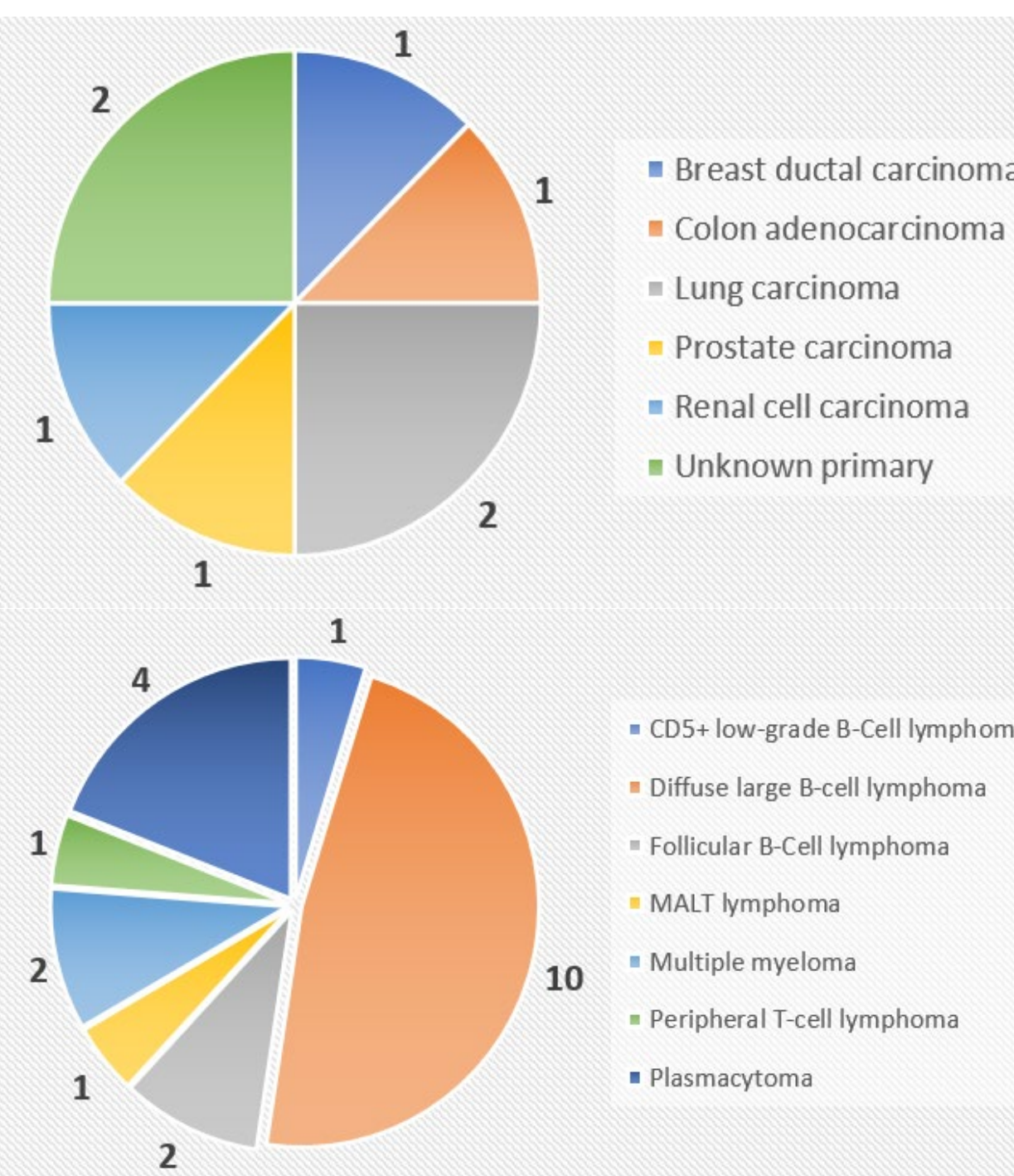


Figure 1: Classification of Cases. (a) Origin of the primary for metastatic diseases. (b) Disease classification for lymphoid neoplasms.

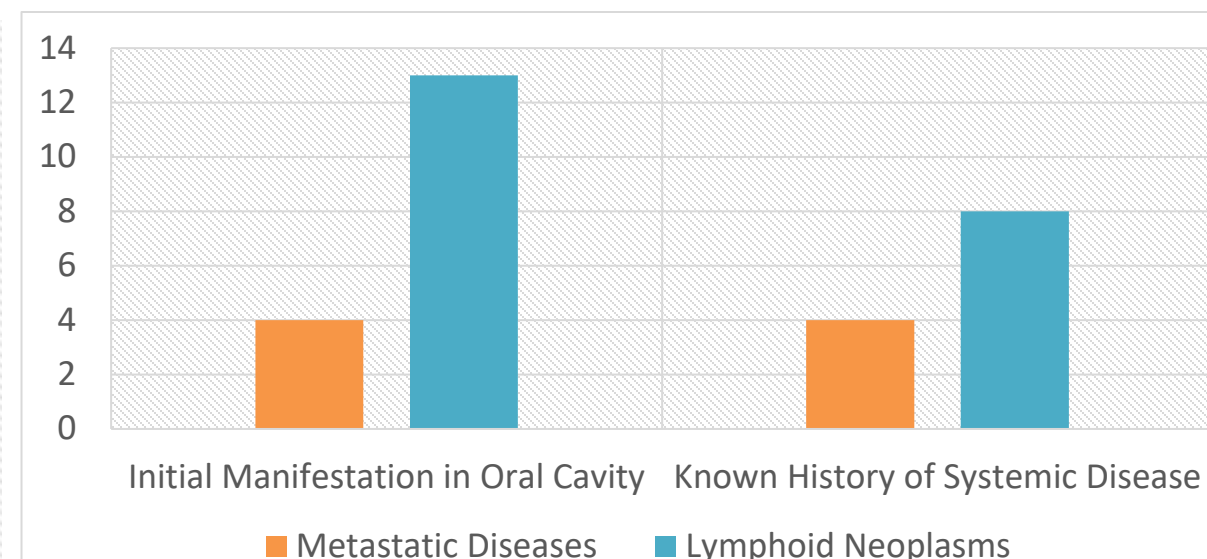


Figure 2: Initial Manifestation vs. Known History. 4 metastatic disease and 13 lymphoid neoplasm cases presented first in the oral cavity. 4 metastatic disease and 8 lymphoid neoplasm cases had prior known history of systemic disease.

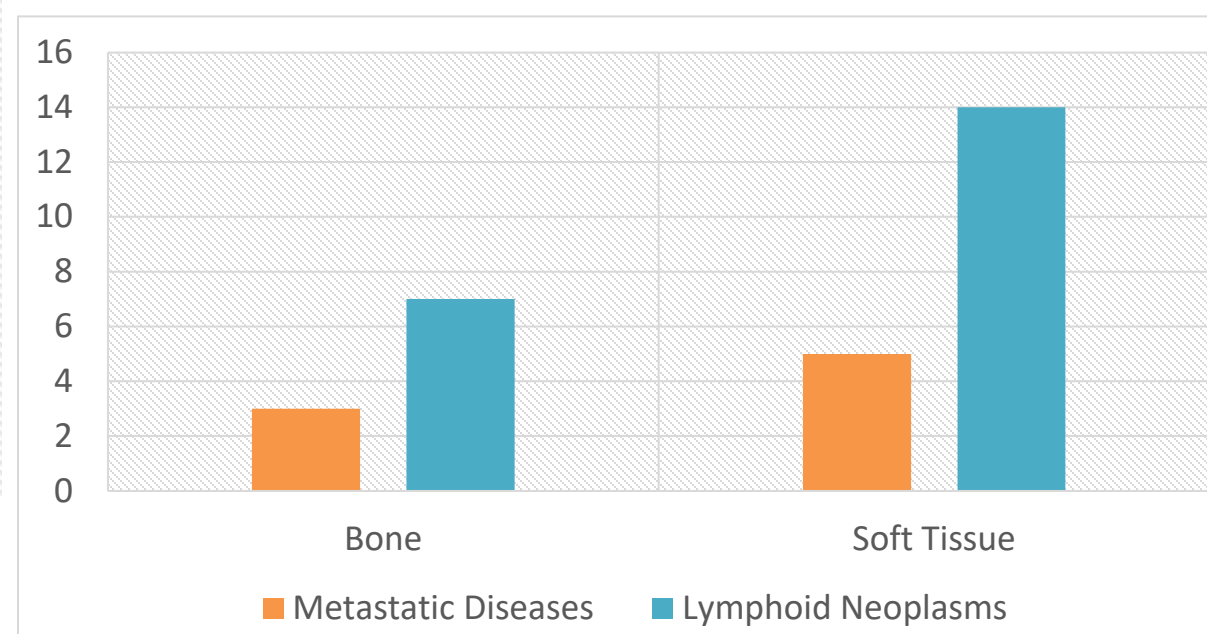


Figure 3: Bone vs. Soft Tissue. 3 metastatic disease and 7 lymphoid neoplasm cases presented in bone. 5 metastatic disease and 14 lymphoid neoplasm cases presented in soft tissue.

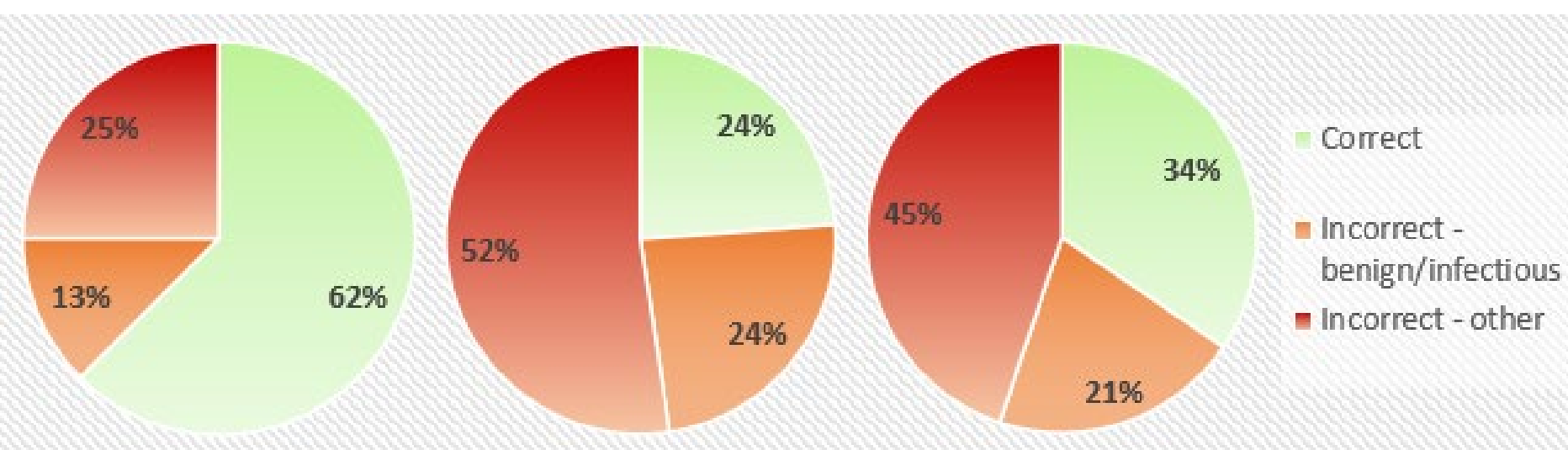


Figure 4: Correct vs. Incorrect Clinical Diagnoses. (a) Metastatic diseases, (b) Lymphoid neoplasms, and (c) overall. More clinical diagnoses were correct for metastatic diseases than lymphoid neoplasms. Overall, there were more incorrect clinical diagnoses.

Table 1: Summary Table of Oral Manifestations of Metastatic Diseases and Lymphoid Neoplasms. 29 total cases were identified, 8 cases of metastatic diseases and 21 cases of lymphoid neoplasms.

Age at Diagnosis	Sex	Biopsy Diagnosis	Biopsy Location	Clinical Diagnosis/ Presentation	Known History of Systemic Disease
Metastatic Diseases					
44	F	Metastatic adenocarcinoma of colon	L retromolar area	Squamous cell carcinoma vs. metastasis	Yes
56	F	Metastatic adenocarcinoma of ductal breast	L mandible	Metastatic breast carcinoma, destructive lytic lesion infiltrating muscles of mastication	Yes
73	F	Metastatic carcinoma of lung	L posterior mandible #19	Persistent swelling, reactive periostitis post root canal therapy	No
76	F	Metastatic carcinoma of lung	R mandibular vestibule #28	Neoplasm, firm swelling and infection unresponsive to root canal therapy	Yes
74	M	Metastatic carcinoma of prostate	L mandible #19&20	Metastatic prostate, pain and unresolving periapical radiolucency	Yes
47	M	Metastatic carcinoma of renal cell carcinoma	R posterior maxillary gingiva distal to #2	Metastatic renal vs. squamous cell carcinoma	No
83	F	Metastatic cribriform adenocarcinoma of unknown primary	L level IIA lymph node	R/o lymphoma	No
88	F	Poorly differentiated metastatic disease of unknown primary	R mandibular gingiva	Pyogenic granuloma	No
Lymphoid Neoplasms					
83	F	CD5+ low grade B-cell lymphoma	R floor of mouth	Ranula, swelling	Yes
52	M	Diffuse large B-cell lymphoma (DLBCL), non-germinal center type	R maxilla	Malignancy r/o lymphoma, soft tissue swelling	Yes
63	F	DLBCL	L mandibular gingiva	Candidiasis, large ulcer	No
54	M	DLBCL	R maxillary buccal vestibule #5&6	Firm swelling, paresthesia, no drainage, soft tissue lesion	No
90	F	DLBCL	L upper lip	Lymphoma vs. sarcoma, raised lesion	No
67	F	DLBCL	R palate	-	No
84	M	DLBCL	R maxillary gingiva	Fungating gingival mass	Yes
84	F	DLBCL	Soft palate	Salivary gland tumor, ulcerated palatal nodule	Yes
37	F	DLBCL	L mandible	Osteomyelitis r/o malignancy	No
68	M	DLBCL, non-germinal center type	R sinus contents	-	No
32	F	DLBCL, non-germinal center type	Anterior maxilla #7&8	Ameloblastoma r/o carcinoma, 3x2.5 cm radiolucency	No
72	M	Follicular B-cell lymphoma	L mandibular gingiva	Progressively enlarging soft tissue mass	No
69	F	Follicular B-cell lymphoma	Gingiva	-	Yes
77	M	MALT lymphoma	Palate	Squamous cell carcinoma, swelling with center ulceration	No
72	M	Multiple myeloma	R mandibular buccal vestibule	Multiple myeloma	No
57	M	Multiple myeloma	L body of mandible	Multiple myeloma, lytic lesion	Yes
57	F	Peripheral T-cell lymphoma	R maxilla	Raised blue lesion	No
84	F	Plasmacytoma - anaplastic	L floor of mouth	Aggressive enlarging lesion	No
60	M	Plasmacytoma c/w h/o multiple myeloma	L mandible	Lytic lesion	Yes
55	F	Plasmacytoma r/o Multiple myeloma	L mandible	Swelling of mucobuccal fold	Yes
68	M	Plasmacytoma r/o Multiple myeloma	R maxillary & mandibular gingiva	Peripheral giant cell granuloma, dusky red exophytic mass	No

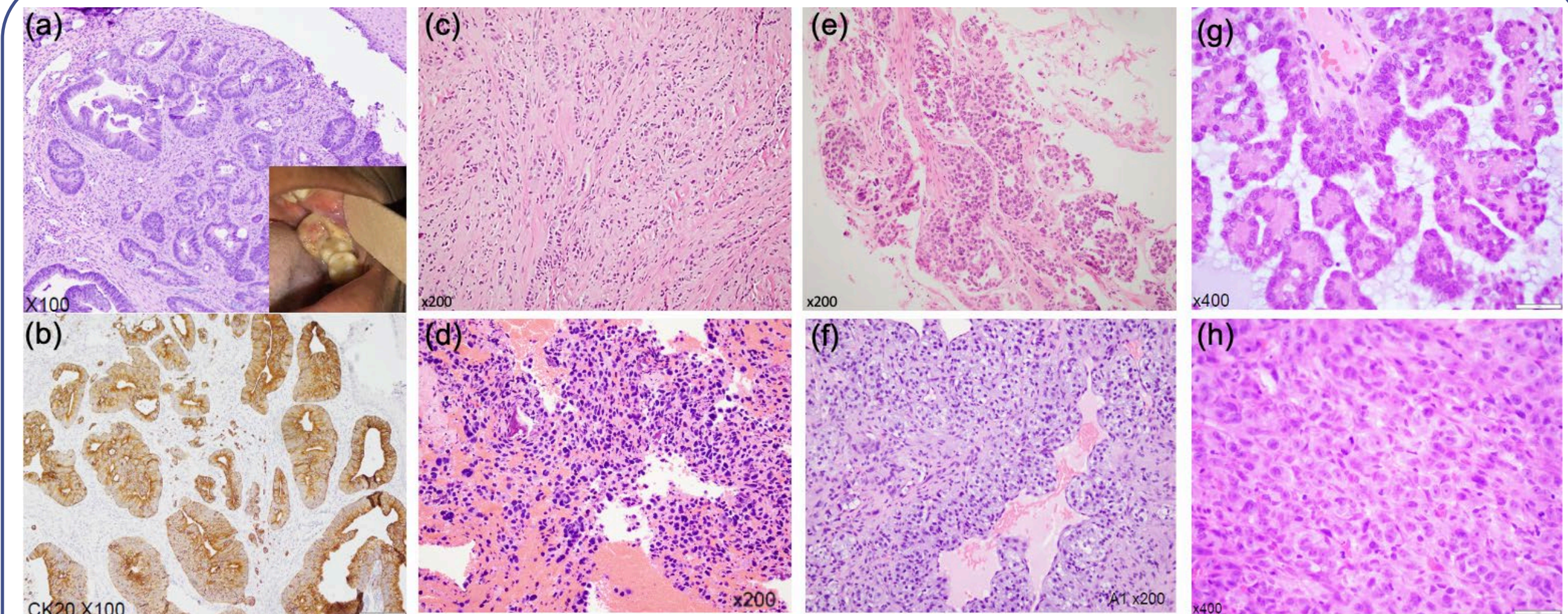


Figure 5: Representative Histological Slides of Oral Manifestations of Metastatic Diseases. (a) Metastatic adenocarcinoma of colon, H&E, 100x with clinical photo of red mass near left retromolar area. (b) Metastatic adenocarcinoma of colon, CK20+, 100x. (c) Metastatic adenocarcinoma of ductal breast, H&E, 200x. (d) Metastatic carcinoma of lung, H&E, 200x. (e) Metastatic carcinoma of prostate, H&E, 400x. (f) Metastatic carcinoma of renal cell carcinoma, H&E, 200x. (g) Metastatic cribriform adenocarcinoma of unknown primary, H&E, 400x. (h) Poorly differentiated metastatic disease of unknown primary, H&E, 400x.

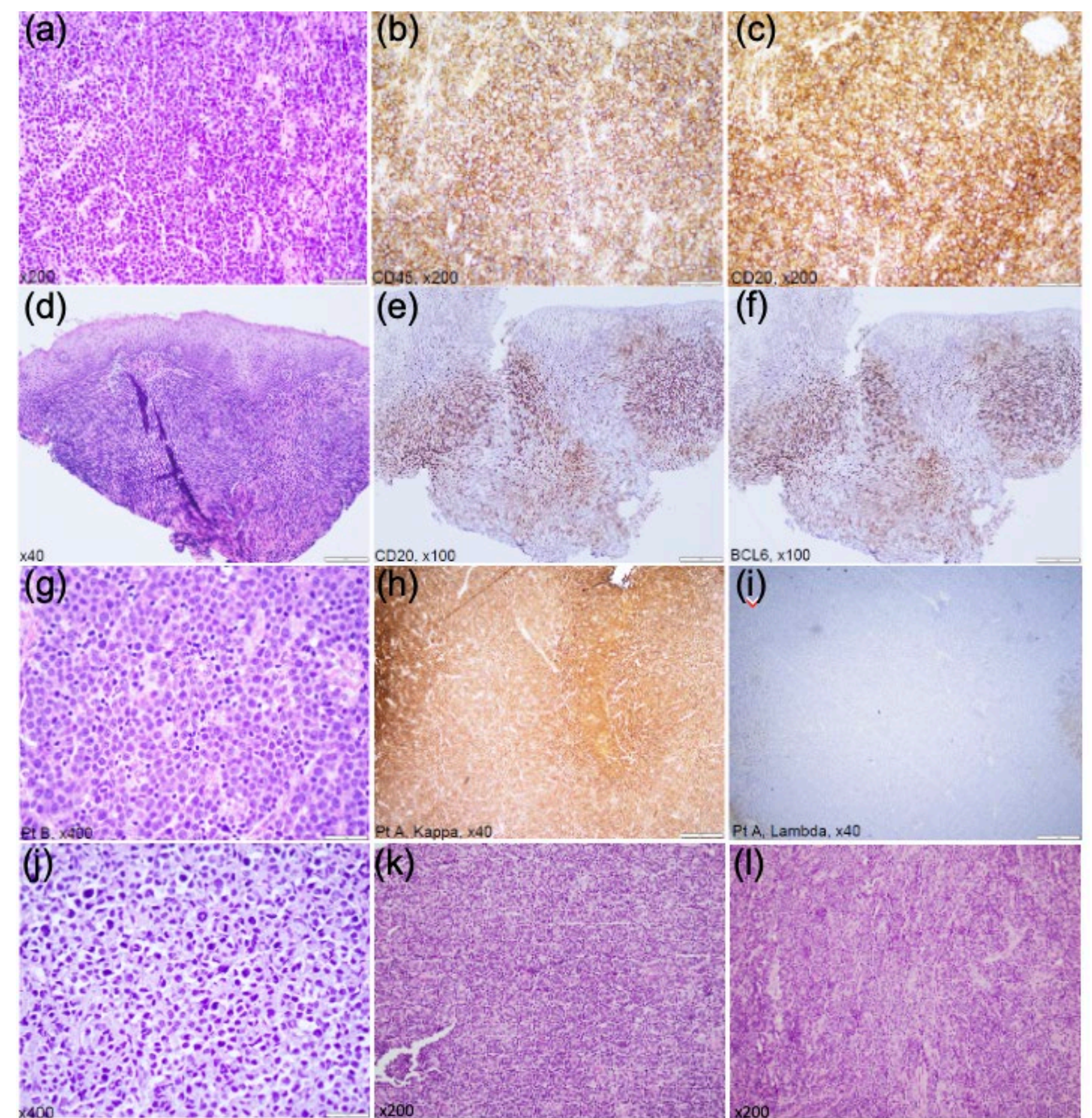


Figure 6: Representative Histological Slides of Oral Manifestations of Lymphoid Neoplasms. Diffuse large B-cell lymphoma (DLBCL) (a) H&E, 200x (b) CD45+, 200x (c) CD20, 200x. Follicular B-cell lymphoma (d) H&E, 40x (e) CD20+, 100x (f) BCL6+, 100x. Multiple myeloma (g) H&E, 400x (h) Kappa, 40x (i) Lambda, 40x. (j) Anaplastic plasmacytoma, H&E, 400x. (k) MALT lymphoma, H&E, 200x. (l) Peripheral T-cell lymphoma, H&E, 200x.

CONCLUSION

Although rare, metastatic disease and lymphoid neoplasms can present in various ways in the oral cavity. In a portion of patients, the oral lesion is the initial manifestation of the systemic disease. Hopefully, recognition of the clinical presentation of these diseases will allow for earlier intervention and potentially better prognosis.

ACKNOWLEDGEMENTS

I would like to thank the CUIMC Department of Oral Pathology, especially Dr. Elizabeth Philipone, for all of their support and guidance on this project. This research was supported by a College of Dental Medicine Summer Research Fellowship.